

BREED VARIATIONS IN THE DISTRIBUTION OF OSTEOARTICULAR LESIONS IN HORSES AT WEANING

Robert, C.*, Jacquet, S., Valette, J.-P., Denoix, J.-M.

UMR INRA-ENVA “Biomécanique et Pathologie Locomotrice du Cheval”
Ecole Vétérinaire d’Alfort, 7, avenue du Général de Gaulle, 94704 Maisons-Alfort, France

*Corresponding author: crobert@vet-alfort.fr

Abstract:

Juvenile Developmental Orthopaedic Diseases (DOD) affect most horse breeds and their occurrence is reported to be increasing. In order to establish the prevalence of DOD in French breed horses, 134 Thoroughbreds (Tb), 161 French Trotters (FT) and 98 Selle Français (SF) foals kept on 21 stud farms were examined radiographically at weaning. Radiographic files (including views from the front and hind interphalangeal and fetlock joints, carpi, hocks and stifle joints) were analysed by 3 veterinarians. For each joint, osteoarticular lesions were graded according to a standardised protocol depending on their severity. The scores of all the images on the 10 radiographs were added to calculate a global radiographic score. Differences in the distribution of the lesions were evaluated using an analysis of variance. SF were globally more severely affected than FT and Tb ($p<0.001$). Considering the regional distribution of the lesions, SF were more severely affected on the front fetlock ($p<0.001$), on the dorsal aspect of the hind fetlock ($p<0.001$) and on the femorotibial joint ($p<0.05$). FT were more severely affected on the plantar aspect of the hind fetlock ($p<0.001$) and the tibiotarsal joint ($p<0.01$). The present study shows that osteo-articular lesions differ between breeds independently of their use and training regimens.

Key words: horse, radiography, developmental orthopaedic disease, breed

INTRODUCTION

Osteochondrosis and other developmental orthopaedic diseases often affect young horses, with recognisable radiological changes developing within the first year of life (Hope 1984). The etiopathogenesis of developmental skeletal problems is not known precisely; heredity, nutrition, endocrinologic dysfunction and biomechanical forces are commonly considered to contribute to the disease (Jeffcott 1991). Numerous articles have been published on isolated occurrences of osteochondrosis, mainly in Standardbreds. However, few data are available in other breeds, and consequently the breed predisposition to the different DOD has not been established.

The objectives of this study were to summarise the radiographic findings of routine examinations performed on foals at weaning, and to determine if there were differences in the location of the lesions between 3 breeds, specifically French Trotters, Thoroughbreds and Selle Français horses.

MATERIALS AND METHODS

Horses

In a longitudinal study, 393 foals were checked at least 3 times between birth and weaning for obtaining information on their body development, feeding management, rearing conditions and locomotion. Foals were born in 2002, 2003 or 2004 in 21 breeding farms in Normandy, the larger horse breeding area in France. They belong to the three main French breeds with 161 French Trotters (FT), 134 Thoroughbreds (Tb) and 98 Selle Français (SF). There were approximately equal numbers of males (total number of 187) and females (206). The management, feeding and grazing routines varied between farms, but were in accordance with the practice of French stud farms for each breed. The general medical care and health among the foals was of good standard.

Protocol

At weaning, the 393 foals were submitted to routine radiographic exam. Foals were required to be at least 4 months of age. Mean age was 172 ± 38 days (mean \pm SD).

The radiographic examinations were performed in the farms using a mobile radiographic unit (Atomscope HF-80) with fast rare-earth intensifying screens (Kodak Lanex Fast) and high-speed film (Kodak T-Mat G). The foals were systematically sedated using a combination of romifidine (Sédivet®) and morphine hydrochloride.

The digits (including the interphalangeal and fetlock joints) in the front- and the hind-limbs, the hocks and the stifles were examined with a lateromedial view. The carpi were examined using dorsopalmar views. Therefore, the radiological examination of each foal comprised 10 views (fig. 1).

All radiographs were evaluated by 3 experienced equine veterinarians working together. For the 14 anatomical sites identified in the areas subjected to radiography, all the lesions were localised and graded using the following scale:

- 1 - Radiographic Finding of Little Significance (mild modelling for instance)
- 2 - Mild Abnormal Radiographic Finding
- 3 - Moderate Abnormal Radiographic Finding
- 4 - Severe Abnormal Radiographic Finding

Then a gravity score was given (table 1) to each lesion according to its severity: the scores on the 14 sites were added to calculate the radiographic score (RS).

Data analysis

Differences between breeds for number of lesions and severity scores were tested using an analysis of variance. All tests were run using the SAS programme for Windows. The level of significance was set at $P < 0.05$.

RESULTS

The multivariate analysis showed that there was no significant difference between males and females for the distribution of the lesions. There was no effect of the year of birth either.

Prevalence of the lesions

The incidence and location of the different radiographic findings are summarised in Table 2. Only 128 foals (32.6%) had no detectable radiographic abnormalities. The average number of lesions per foal was 1.5 (range 1-10).

Mean RS was 2.3 (range 0-22). There was a significant difference between breeding farms for the RS; the mean value of RS varied from 0.3 to 5.8 between the 21 farms.

SF foals were globally more severely affected than FT and Tb. The proportion of foals with no radiographic lesion was lower, the mean number of lesions was higher and they had a higher RS ($p < 0.001$).

Distribution of the lesions

Among all the investigated joints (table 3), the dorsal part of the hind fetlock showed the highest prevalence of lesions with 75 foals affected (20.2%). Most of the lesions were dorsal fragments (33 lesions). The other lesions were changes in the dorsal aspect of the distal metatarsus and modelling of articular margins.

The second higher incidence of lesions was encountered in the carpus with 74 animals affected (19.9%). However, these lesions were on average not as severe as those located on the other joints. Most of these lesions were small cystic lesions or fragmentation of the ulnar carpal bone.

The third site was the stifle with 17.5% of the animals affected. Lesions on the lateral trochlear ridge of the femur were predominant (68 lesions), compared to the 5 lesions of the medial trochlear ridge of the femur and the 6 lesions of the condyles.

The incidence of radiographic findings was high in the front fetlock with 62 foals affected (16.7%). The most frequent lesions were dorsal fragmentation or modelling (31 lesions) and physitis (36 lesions).

The prevalence of lesions in the plantar aspect of the hind fetlock and the proximal and distal part of the hock was lower. Most of the lesions found in the metatarsophalangeal joint were plantar osteochondral fragments (24 lesions). As usual in the tarsocrural joint, the classical lesion at the dorsal part of the intermediate ridge of the tibia (37 lesions) outnumbered those found in the lateral (14) or medial (3) trochlea of the talus. Lesions observed at the intertarsal and tarsometatarsal joints were osteophytes or juvenile degenerative joint disease (10 lesions) and collapse of the tarsal bones (7 limbs affected).

The more severe lesions (graded 8) were located in the tarsus and the stifle (fig. 2).

Breed effects in the distribution of the lesions

The statistical analysis revealed significant variations among breeds in both the location of the lesions and the occurrence of the lesions per site (table 3).

In the SF foals, lesions were predominantly located on the dorsal aspect of the hind fetlock (34.7% of the foals affected), the stifle (32.7%), the front fetlock (31.6%) and the proximal part of the hock (16.3%).

In the FT foals, lesions were predominantly located on the carpus (19.9% of the foals affected), the plantar aspect of the hind fetlock (16.8%) and the proximal part of the tarsus (14.3%).

In the Tb foals, lesions were predominantly located on the front fetlock (17.9% of the foals affected), the dorsal aspect of the hind fetlock (16.4%) and the carpus (15.7%).

There was no breed effect for the prevalence of the lesions in the pasterns, the carpus, the distal part of the tarsus and the femorotibial joint.

Conversely, lesions of the front fetlock, the dorsal aspect of the hind fetlock and the femoropatellar joint were more frequent in the SF foals.

Lesions of the plantar aspect of the hind fetlock were more frequent in the FT foals.

Lesions of the proximal part of the tarsus and the front foot were rare in the Tb.

Lesions of the front fetlock were rare in the FT.

DISCUSSION

Data collection and analysis

Osteochondrosis (OC) develops early in life and the first radiological signs can be detected before the age of 3 months (Carlsten et al. 1993). The radiological monitoring of OC lesions in hock and stifle showed that OC is a dynamic process (Dik et al. 1999). Lesions become apparent and subsequently can progress, regress or completely disappear until a certain « point of no return », which is not identical for all joints. The results presented here are valid for foals but are not representative of the osteoarticular status of older horses.

It was chosen to examine foals at weaning because it is common now in big stud farms to perform screening radiographic exams on their foals between 6 and 9 months of age in order to make a selection and to prepare the sales.

The radiological views chosen here are optimal to detect the more frequent DOD lesions. For practical and economical reasons, it was decided not to include oblique views of the fetlocks, carpus and tarsus. This means

that some lesions may have been missed, but it was preferred to increase the number of foals instead of the number of radiographic views.

Prevalence of the lesions

There have been a number of descriptive studies concerning the occurrence of DOD or OC in the horse before. The prevalence of the lesions varies significantly between studies. These differences between investigations appear to arise from the use of different horse populations, from various definitions of OC, from the use of different radiographic screening as well as the integration of partly pre-selected animals.

Based on a sample of 624 Warmblood foals on 83 German breeding farms, Schober et al. (2003) found 32% of the tested foals revealed positive findings in fetlock and hock. For Alvarado et al. (1989), only 27.4% of the Standardbreds had no detectable radiographic abnormalities. Our results compare well with these studies with 32.6% of the foals with no lesion at all and 62.8% without any ARF.

Apart from the population, prevalence of OC in the different joints varies between 12 and 30% in literature.

In the present study, the proportion of FT with palmar/plantar osteochondral fragments is comparable to previous studies in Standardbreds trotters (Grondahl et al. 1993, Sandgren et al. 1993, and Storgaard et al. 1997). The incidence of hock OC in our study falls in the range of earlier reports too (Schougaard et al. 1990, Carlsten et al. 1993, Grondahl et al. 1993, Storgaard et al. 1997, Brehm and Staeker 1999).

On the contrary, two studies in Thoroughbreds report much smaller prevalence of DOD (Kane et al. 2003, Pagan and Jackson 1996). The first one was performed on yearlings before the sales and the results may be biased by a pre-selection of the animals. The results of the second one come from a unique breeding farm and cannot be generalised to the Kentucky population: in our study, the incidence of DOD significantly varied between farms.

It is difficult to compare our results in SF foals to the other studies in Warmblood foals. Barneveld and van Weeren (1999) report a higher prevalence of lesions in a population of foals genetically predisposed to OCD. Schober et al. (2003) found fewer foals affected in the fetlock and hock than in our study, but the type of lesions considered is not defined precisely.

Breed variations

Only one other study (Strömberg and Rejnö 1978) tried to compare the occurrence of DOD in different breeds. It was found that osteochondritis dissecans of the stifle joint was more common than the one in the hock joint in Thoroughbreds and Halfbreds, while the lesion in the hock joint was most common in Standardbred trotters. These results come from Swedish horses between 1 and 6 years referred to the clinics for slight lameness. They are not representative of the whole population of horses in Sweden.

Nevertheless, differences between breeds are quite easy to explain. The appearance of OC may depend on many interacting genetic and environmental factors (Schober et al. 2003).

Osteo-articular lesions may be influenced by the type and load of activity, conformation defects and developmental abnormalities. Van Weeren and Barneveld (1999) demonstrated that exercise may have some influence on the appearance and the distribution of OC lesions and Wilke et al. (2003) showed that foals with little exercise within their first months of life had highest incidences of OC.

It has been demonstrated that genetic factors were involved in the aetiology of tibiotarsal OC (Schougaard et al. 1990). It was also proved that the incidence of OC in Standardbred trotters was related to body size (Sandgren et al. 1993) and that weight gain rate affected the occurrence of lesions in the femoropatellar joint (van Weeren et al. 1999).

As growth rate, conformation and body weight, as well as rearing conditions are different between breeds, all these parameters can interact to make the distribution of OC different between breeds.

CONCLUSION

This is the first study using a unique standardised protocol to compare the osteo-articular status of foals from different breeds born in the same breeding area. It has demonstrated that there were significant differences between SF, FT and Tb at weaning in both the prevalence and the distribution of radiographic lesions. A radiographic survey over a longer period is currently in progress to examine the breed variation at a later age.

ACKNOWLEDGEMENTS

This study was supported by the Conseil Régional de Basse Normandie, the Haras Nationaux and the INRA.

REFERENCES

- Alvarado, A., Marcoux, M. and Breton, L. (1989) The incidence of osteochondrosis in a Standardbred breeding farm in Quebec. In: *Proceeding of American Association of Equine Practitioners* 293-307.
- Barneveld, A. and van Weeren, P. R. (1999) Conclusions regarding the influence of exercise on the development of the equine musculoskeletal system with special reference to osteochondrosis. *Equine Veterinary Journal* Suppl. 31 112-119.
- Brehm, W. and Staeker, W. (1999) Osteochondrosis (OCD) of the tarsocrural joint of standardbred trotters - correlation between radiographic findings and racing performance. In: *Proceeding of American Association of Equine Practitioners* 164-166.
- Carlsten, J., Sandgren, B. and Dalin, G. (1993) Development of osteochondrosis in the tarsocrural joint and osteochondral fragments in the fetlock joint of Standardbred trotters. I. A radiological survey. *Equine Veterinary Journal* supplement 16 42-47.
- Dik KJ, Enzerink E, van Weeren PR. (1999) Radiographic development of osteochondral abnormalities, in the hock and stifle of Dutch Warmblood foals, from age 1 to 11 months. *Equine Veterinary Journal* Suppl. 31 9-15.
- Grondahl, A. M. and Dolvik, N. I. (1993) Heritability estimations of osteochondrosis in the tibiotarsal joint and of bony fragments in the palmar/plantar portion of the metacarpo- and metatarsophalangeal joints of horses. *Journal of the American Veterinary Medicine Association* 203 (1), 101-104.
- Hoppe, F. (1984) Radiological investigations of osteochondrosis dissecans in Standardbred Trotters and Swedish Warmblood horses. *Equine Veterinary Journal* 16 (5), 425-429.
- Jeffcott, L. B. (1991) Osteochondrosis in the horse - searching for the key to pathogenesis. *Equine Veterinary Journal* 23 (5), 331-338.
- Kane, A. J., Park, R. D., McIlwraith, C. W., Rantanen, N. W., Morehead, J. P. and Bramlage, L. R. (2003) Radiographic changes in Thoroughbred yearlings. Part 1: Prevalence at the time of the yearling sales. *Equine Veterinary Journal* 35 (4), 354-365.
- Pagan, J. D. and Jackson, S. G. (1996) The incidence of developmental orthopaedic disease on a Kentucky Thoroughbred farm. In: *Proceeding of 18th AEVA Bain-Fallon Memorial Lectures* 121-128.
- Sandgren, B., Dalin, G. and Carlsten, J. (1993) Osteochondrosis in tarsocrural joint and osteochondral fragments in the fetlock joints in Standardbred trotters. I. Epidemiology. *Equine Veterinary Journal* (suppl. 16), 31-37.
- Schober, M., Coenen, M., Distl, O., Hertsch, B., Christmann, L. and Bruns, E. (2003) Estimation of genetic parameters of osteochondrosis (OC) in Hanoverian Warmblood foals. In: *Proceeding of 54th Annual Meeting of Europe Association for Animal Production* Rome, Italy
- Schougaard, H., Falk Ronne, J. and Philipsson, J. (1990) A radiographic survey of tibiotarsal osteochondrosis in a selected population of trotting horses in Denmark and its possible genetic significance. *Equine Veterinary Journal* 22 (4), 288-289.
- Storgaard Jorgensen, H., Proschowsky, H., Falk-Ronne, J., Willeberg, P. and Hesselholt, M. (1997) The significance of routine radiographic findings with respect to subsequent racing performance and longevity in Standardbred trotters. *Equine Veterinary Journal* 29 (1), 55-59.
- Strömberg, B. and Rejnö, S. (1978) Osteochondrosis in the horse. I. A clinical and radiologic investigation of osteochondritis dissecans of the knee and hock joint. *Acta Radiologica* suppl. 358 139-152.
- van Weeren, P. R. and Barneveld, A. (1999) The effect of exercise on the distribution and manifestation of osteochondrotic lesions in the Warmblood foal. *Equine Veterinary Journal* suppl. 31 16-25.
- Wilke, A., Coenen, M., Distl, O., Hertsch, B., Christmann, L. and Bruns, E. (2003) Effect of locomotion on the development of osteochondrosis in Hanoverian Warmblood foals. In: *Proceeding of 54th Annual Meeting of Europe Association for Animal Production* Rome, Italy

Table 1: Gradation and severity of radiographic findings

Grade	Signification	Score
1	Radiographic Finding of Little Significance (mild modelling for instance) – usually no clinical incidence	1
2	Mild Abnormal Radiographic Finding = little incidence on physical appearance and locomotion	2
ARF 3	Moderate Abnormal Radiographic Finding = often associated with synovial effusion and sometimes lameness	4
4	Severe Abnormal Radiographic Finding = usually associated with synovial effusion and lameness	8

Table 2: Breed variations in the osteo-articular status of the 393 foals

	Total	SF	FT	Tb
number of foals	393	98	161	134
mean RS (s.d.)	2,3 (2,9)	3,5 (3,5)	2,1 (3,0)	1,7 (2,5)
number of foals with no lesion	128	17	59	52
% of foals with no lesion	32,6	17,3	36,6	38,8
number of foals with no ARF	247	52	104	91
% of foals with no ARF	62,8	53,1	64,6	67,9
mean number of lesion (s.d.)	1,5 (1,6)	2,3 (1,9)	1,3 (1,4)	1,1 (1,1)
mean number of ARF (s.d.)	0,6 (1,0)	0,9 (1,4)	0,6 (1,0)	0,5 (0,8)
number of foals with RS>5	38	17	14	7
% of foals with RS>5	9,7	17,3	8,7	5,2

Table 3: Proportion of foals affected by osteo-articular lesions on the different joints
p indicates the breed effect: values with the same letters are not statistically different, NS = non significant.

%	Total	SF	FT	Tb	p
FORELIMB					
Foot	4.9	7.1a	5.6ab	1.5b	<0.05
Pastern	5.7	8.2	6.2	2.2	NS
Fetlock	16.7	31.6a	4.3c	17.9b	<0.0001
Carpus	19.9	21.4	19.9	15.7	NS
HINDLIMB					
Pastern	10.8	14.3	9.3	8.2	NS
Fetlock dorsal	20.2	34.7a	11.8b	16.4b	<0.0001
Fetlock plantar	9.4	4.1b	16.8a	3.0b	<0.0001
Hock proximal	11.6	16.3a	14.3a	3.0b	<0.005
Hock distal	5.7	7.1	4.3	5.2	NS
Stifle	17.5	32.7a	9.3b	13.4b	<0.05

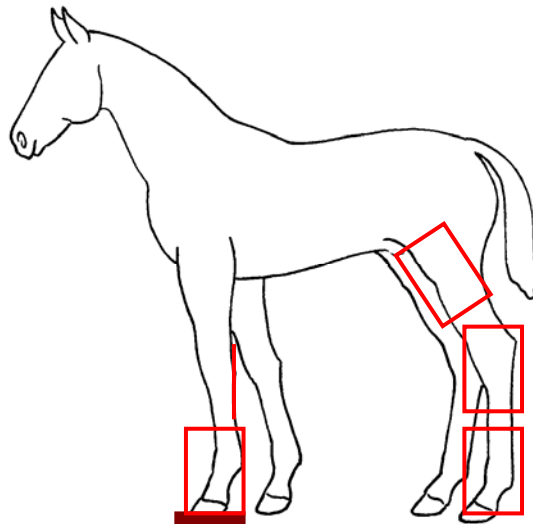


Fig. 1: The radiographic examination of each foal comprised 10 views: lateromedial view of the front- and hind-digits, hocks and stifles, dorsopalmar view of the carpus

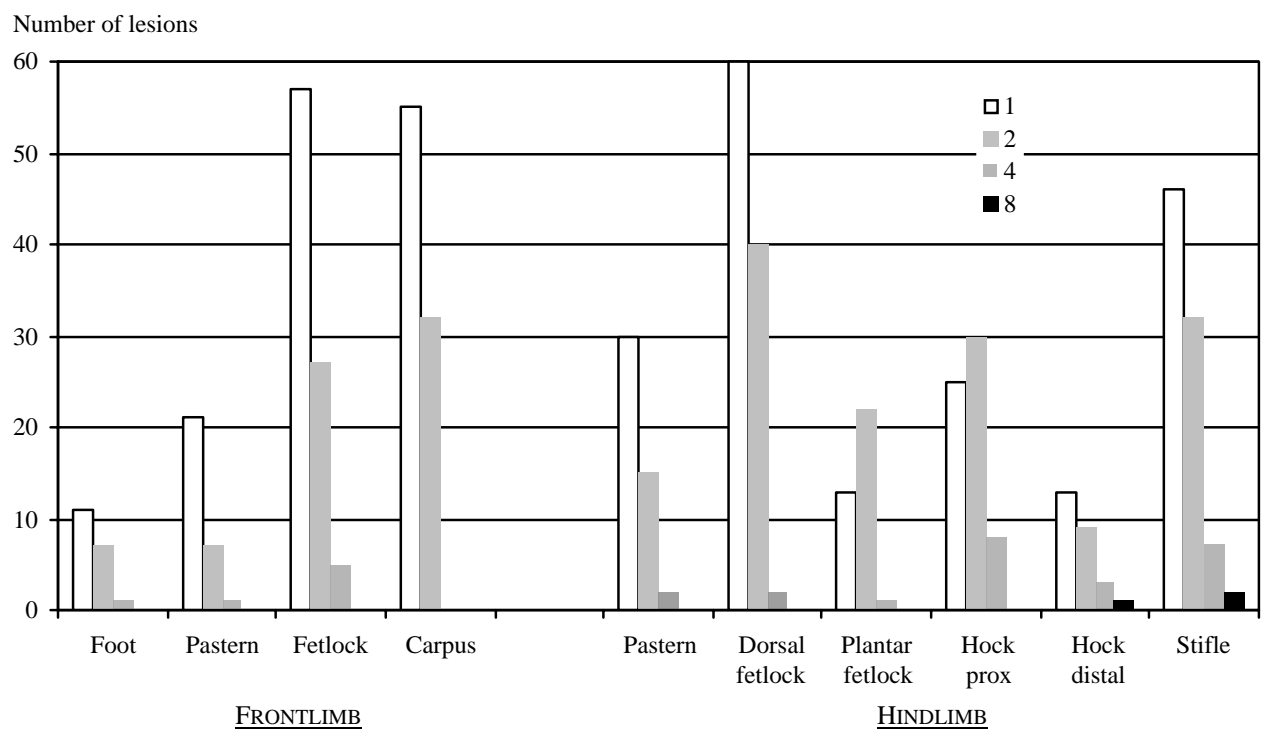


Fig. 2: Distribution of the radiographic findings according to their gravity on the different joints